

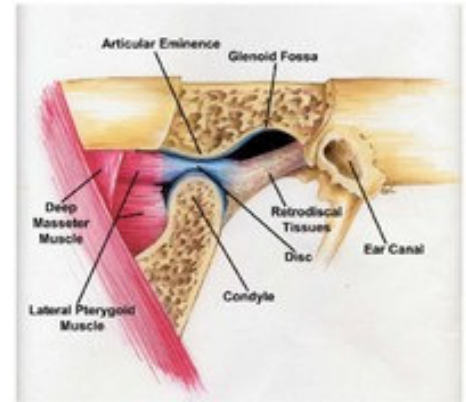
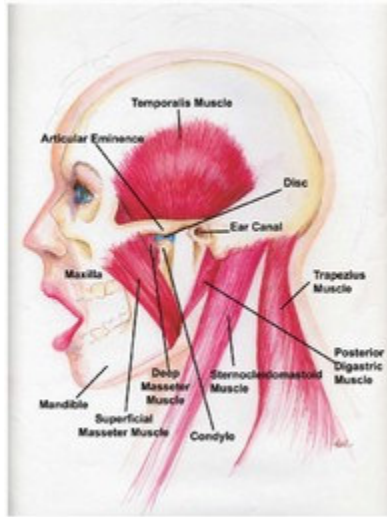
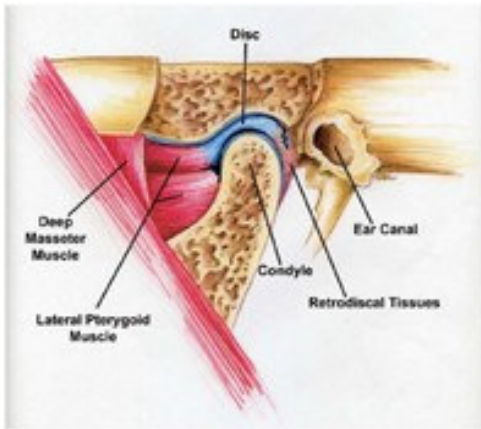
TMJ ANATOMY

The temporomandibular joint or TMJ is a “loose-fitting”, rotating and sliding joint with a fibrocartilage covered, football shaped ball (condyle), fibrous pad (disc), fibrocartilage lined socket (fossa), ligaments, tendons, blood vessels and nerves. The disc functions as a moving shock absorber and stabilizer between the condyle and fossa. As the jaw opens, normally the condyle first rotates and then slides forward within the fossa with the disc between the condyle and the fossa.

NORMAL TMJ MOUTH CLOSED

OPEN MOUTH

NORMAL TMJ OPEN MOUTH



THE MUSCLES OF MASTICATION (jaw muscles) attach to the mandible (lower jaw), maxilla (upper jaw), skull and neck. The muscles of mastication open, close, protrude and laterally move the jaw, enabling you to talk, chew, and swallow. The supporting muscles of mastication (neck and shoulder girdle muscles) stabilize the skull on the neck during jaw function.

http://aaop.avenet.net/index.asp?Type=B_BASIC&SEC=%7BA350EB8C-4F6B-4925-8AF7-3D8D60570F4A%7D